

## Survival of Root Canal Pulp Tissue after Pulpitis

Juni Handajani<sup>1,3</sup>, Tetiana Haniastuti<sup>1,3</sup>, Hayato Ohshima,<sup>2</sup> Etsuro Hoshino<sup>1</sup>

<sup>1</sup>Oral Ecology in Health and Infection, <sup>2</sup>Anatomy and Cell Biology of the Hard Tissue, Niigata University Graduate School of Medical and Dental Science, Niigata, Japan, <sup>3</sup> Department of Oral Biology, Faculty of Dentistry, Universitas Gadjah Mada, Yogyakarta, Indonesia

### Abstract

The aim of this study was to demonstrate the possibility if infected and inflamed pulp tissue survived after the clinical treatment with local application of an antibacterial drug mixture. A total of 48 third molars, consisted with 15 teeth of pulpitis with the clinical symptoms of spontaneous pain, 24 teeth of pulpitis with visible pulp exposure, and 9 teeth diagnosed as necrotic pulp because of vacant coronal pulp-chambers, was included in this study. A combination of 3 antibacterial drugs, *i.e.*, metronidazole, ciprofloxacin, and minocycline (3Mix), was further mixed with macrogol (M) and propylene glycol (P) and used to disinfect pulps of 47 teeth, while the remaining one pulp was not treated as a control. 3Mix-MP was placed onto the dentin floor of cavities, or orifice of root canal, then sealed by glass-ionomer cement and further reinforced by composite resin inlay. Seven days to 19 months after treatment, the teeth were extracted under the informed consents. They were observed by micro-computed tomography (CT) before decalcification with 10% ethylenediamine tetraacetic acid (EDTA) solution (pH 7.0). Immunohistochemistry against Nestin and protein gene product (PGP) 9.5 was performed in addition to Hematoxylin and Eosin, Azan and Giemsa staining. Micro-CT revealed that, in all cases, carious lesions extended to the pulps. Clinical outcomes at the time of extraction were good in all cases without any additional clinical symptoms. Histopathologically, in all cases, damages of pulpal tissue, such as inflammatory cell infiltration and destruction of pulp tissue including the loss of odontoblast layers at the exposed areas, were observed as the consequence of pulpitis. However, in all the 38 cases treated as pulpitis, both of coronal and radicular pulp-tissue survived and retained/restored the pulpal functions demonstrated by positive immunochemical reactions of Nestin and PGP 9.5. In addition, among 9 cases diagnosed as necrotic pulp, 5 cases demonstrated that root canal pulp-tissue remained at apical one-third of root canals with a few inflammatory cells, and Nestin and PGP 9.5 were positive in the remaining pulp-tissue, while in the remaining 4 cases, root canal chambers were entirely vacant with few scattered cells, if any. Disinfection of infected and inflamed pulp-tissue using 3Mix-MP might result in the discontinuance of pulp destruction and the survival of pulp tissue. The present study clearly demonstrated that pulpal tissue survived and retained/restored pulpal functions after LSTR 3Mix-MP treatment even though the cases had once infected and inflamed with spontaneous pain, pulp exposure or partial necrosis of pulp tissue. It should be noted that, when inflamed pulp tissue remained in root canals even the coronal pulp was destructed, it was worth first to disinfect the root canal pulps using 3Mix-MP without removal of them, because the radicular pulp tissue could survive and restored the pulpal functions even after once they had infected and inflamed.

Keywords: disinfection of pulps, histopathology of pulpitis and the treatment, infected dental pulp, LSTR 3Mix-MP

### Introduction

Our *in vitro* study (1-5) demonstrated all bacteria from infected dental pulp were fully sensitive against a combination of three antibacterial drugs, namely ciprofloxacin, metronidazole and minocycline (3Mix). 3mix was used as 3Mix-MP after mixed with macrogol (M) as an ointment base and propylene glycol (P) as excellent carrier (6) of 3Mix through dentinal tubules (7). Thus, even though 3Mix-MP was placed on the bottom of caries cavities over pulp chambers, it penetrated efficiently through dentinal tubules and kill bacteria in the pulpal lesions (7). These findings led to a new treatment system to disinfect dental pulps without pulpectomy and to preserve the pulps (Lesion Sterilization and Tissue Repair (LSTR) 3 Mix-MP Save Pulp Therapy). In fact, 360 cases of pulpitis with spontaneous pain, with caries lesions reaching to pulps on X-ray photos, or with pulp exposure, were treated only with 3Mix-MP medication without pulpectomy, and the pulp vitality was preserved in 95% cases. In the remaining 5 % cases, the pulp sensitivity was lost, probably because the pulps had been necrotic at the time of treatment, but yet the cases were evaluated as clinical success because they had no

clinical symptoms and functioned to bite without any disorders (8). In addition, histopathological evaluation of pulpitis cases with spontaneous pains revealed that coronal pulps were inflamed but the functions retained, indicating that after the infective inflammation ceased, the pulp might recover reversibly (9). Using 3Mix-MP, excellent clinical outcomes have also been reported (8, 10-11).

In the present study, we evaluate histopathologically whether coronal and radicular pulps possibly survived after inflamed and disinfected using 3Mix-MP.

### Materials and Methods

#### *Patients and teeth involved in this study*

Forty-eight 3rd molars from 48patients, 21-49 years old, visited at a private dental clinic in Yogyakarta, Indonesia, between the years of 2004 to 2009, were included in this study. They claimed, as shown in Table 1, spontaneous pain (15 cases), dental caries with pulp exposure (23 cases), and, thus, the teeth were diagnosed as pulpitis (39 cases) according to the conventional diagnosis. Pain on bite with vacant crown pulp chambers was also claimed, and, thus, the teeth were

diagnosed as necrotic pulp (9 cases). Because the antagonistic teeth were lacking, those teeth were practically to extract without endodontic treatment, those were considered to involve in the present study under the ethical clearance approved by the Ethic Committee of Medical Faculty of Gadjah Mada University, Yogyakarta, Indonesia. All the patients were informed on the aim and the expected clinical results, as well as the advantages and the disadvantages of intended treatment prior to inclusion, and they all provided written informed consent. They were treated using 3Mix-MP and, then, extracted for the histopathological evaluation certain periods after the treatment done by a dentist in Yogyakarta. extracted for the histopathological evaluation certain periods after the treatment done by a dentist in Yogyakarta.

#### **Treatment of pulpitis using 3Mix-MP**

After recording clinical symptoms (Table 1), the teeth, except for a tooth for a control evaluation, were treated with application of 3Mix-MP without pulpectomy or root canal instrumentation. Pulp response was examined using an ethyl chloride coolant (Water Ritter GmbH, Germany).

The preparation of 3Mix-MP (7-8, 10-11) were described elsewhere. In short, after removal of the capsules or coating materials that enclose the drug products, each of the drugs was pulverized to fine powders using a porcelain mortar and a pestle, and then stored separately in a tightly capped porcelain container to prevent exposure to light and humidity. A small amount of silica gel in a bag was placed inside the container to maintain low humidity. The powdered drugs were used within a month of preparation. On the day of treatment, powdered ciprofloxacin, metronidazole and minocycline were mixed in a ratio of 1:3:3 (by volume). The vehicle, of an ointment consistency, was prepared separately by mixing macrogol (M; Solbase, Meiji, Tokyo) and propylene glycol (P; Nikko, Japan) in a ratio of 1:1 (by volume). The 3Mix antibiotics and MP vehicle were thoroughly mixed to form 3Mix-MP in a ratio of 7:1 for standard consistency and, then, ball-like particles (1 mm diameter) of 3Mix-MP were prepared. 3Mix-MP preparation should be prepared and used on the day of preparation.

The clinical treatment using 3Mix-MP (8, 10-11) were described elsewhere. In short, carious dentin including softened dentin was not removed at all intentionally. Especially, in pulpitis cases, care was taken not to damage the pulp during the preparation. Before the placement of 3Mix-MP, the cavity was dried up using a cotton ball. In necrotic pulp cases, a medication cavity (1mm diameter x 2mm depth) was prepared at the orifice of root canal. The dentinal walls of the preparation were treated with 12% EDTA, pH 7.0, for 1 min to remove the smear layer. Patients were not anesthetized with local anesthesia, because the above procedures do not give pain to patients. Under anesthetized conditions, dentists may not recognize damaging the pulps and giving pain to patients.

For pulpitis cases, a 1 mm diameter ball-like particle of 3Mix-MP preparation was placed on the bottom of caries cavities, not directly onto exposed pulp, and in necrotic pulp cases, a ball-like 3Mix-MP was placed at the medication cavity, and, using a cotton ball, pressed to a thin layer on the cavity floor. Then, a first layer of glass-ionomer cement (Fuji IX, GC, Tokyo) was applied to seal 3Mix-MP with care not to express 3Mix-MP out of the cavity. The cavity was then entirely sealed with the second layer of glass-ionomer cement. Then, a widely open-angled restoration cavity for a composite resin-inlay restoration was made as small in size as possible. The wider margin areas on enamel were provided to reinforce the seal and to ensure sufficient adherence and retention of the composite resin-inlay restoration following etching with 35% phosphoric acid solution. The resin-inlay, made using the Clearfil composite resin (Kuraray, Tokyo) on the tooth, was cemented using the Panavia F 2.0 Estenia Cementing Kit (Kuraray, Tokyo) according to the manufacture's manual. In certain cases with undermined cusps, an onlay form of the composite resin restoration was provided. In most cases, the treatment was completed in one visit.

Post-treatment observations were made to assess the changes of clinical symptoms. Pulp sensation evoked by ethyl chloride coolant was also confirmed. In addition, any pain or discomfort on biting or chewing on the treated tooth was noted.

The clinical outcomes were defined as follows at the time of extraction 7 days to 19 months after treatment. A "good" clinical outcome saving pulp was defined as the lack of any spontaneous pain, no pain on bite and the presence of pulpal responsiveness to cold stimuli. In addition, the cases of necrotic pulp were evaluated as good when no clinical symptoms and no pain on bite were reported even if the pulpal responsiveness was lacking, and thus, these cases were clinically good and no further treatment was needed.

#### **Histopathological examination of pulp tissue**

Samples were checked using a Micro-CT (Elescan, Nittetsu Elex, Osaka, Japan) for pulp exposure and dentin bridge formation. All of the teeth were, then, decalcified with 10% (EDTA) at pH 7.0 for around 8 months, and, then, embedded in paraffin. The serial sections of an average 4µm in thickness were stained with Hematoxylin-Eosin (HE) for the evaluation of pulp cell organization, with Azan for fibroblasts and collagen fibers, and with Giemsa for infiltrated inflammatory cells.

After treated with 3% hydrogen peroxide to quench the endogenous peroxidase activity, some sections were immunostained following the manufacture procedure of N-Histofine staining kit (Nichirei Bioscience, Japan) using anti human PGP 9.5 antibodies (UltraClone, Japan) for nerve innervations, and using polyclonal anti-Nestin antibodies (Millipore, Temecula, CA) for odontoblast function and intermediate filaments. The applied antibodies were diluted to 1:500.

Table 1. Clinical evidence before treatment

No. of cases	Visible Pulp expo-sure	Spontaneous pain	Pain on cold	Pain on bite	Pulp response*	Conventionally suggested	
						Diagnosis	Treatment
15	-	+	8	-	+	Pulpitis	Pulpectomy
23	+	-	+	-	+	Pulpitis	Pulpectomy
5	+	-	-	+	-	Necrotic	Root canal treatment
4	+	-	-	-	-	Necrotic	Root canal treatment

\*Pulp response: examined using an ethyl chloride coolant.

Additional untreated one case was diagnosed as pulpitis with pulp exposure.

## Result

### **Clinical evidence before and after the treatment**

Before LSTR 3Mix-MP treatment, as shown in Table 1, 38 teeth had been diagnosed as pulpitis. Among them, 15 cases had claimed spontaneous pain but visible pulp exposure was not observed, while other 23 cases claimed no spontaneous pain with visible pulp exposure at the time of diagnosis. Prolonged cold-water pain evoked in 31 cases, while, in other 7 cases, the pain was slight and ceased within a few seconds.

All the 38 teeth were not painful on bite. In 23 cases having visual pulp exposure, spontaneous pain was not claimed at the time of treatment, although pain on cold water was claimed. Among 9 teeth diagnosed as necrotic pulp, of which coronal pulp chambers had opened widely and vacant, 5 teeth revealed pain on bite, while 4 did not. Pulpal responsiveness to cold was not detected in all of 9 cases at the time of diagnosis.

An additional tooth, diagnosed as pulpitis with pulp exposure without spontaneous pain, was extracted without treatment.

Table 2. Clinical evidence after treatment using 3Mix-MP

No. of cases	Diagnosed as	Spontaneous pain	Pain on cold	Pain on bite	Pulp sensitivity
15	Pulpitis	-	2*	-	+
23	Pulpitis	-	3*	-	+
5	Necrotic pulp	-	-	-	+
4	Necrotic pulp	-	-	-	-

\* Slight pain for a few second.  
Additional one case was not treated.

After the treatment, all patients did not claim any additional clinical disorders until the time of extraction for 7 days to 19 months after the treatment.

As shown in Table 2, among 15 cases diagnosed as pulpitis with spontaneous pain and extracted 7 days-10 months after the treatment, the patients reported that pain was disappeared quite soon in all the cases after the treatment. Among 8 cases that had claimed prolonged cold water pain before the treatment, the pain still remained in 2 cases 2 week and 10 months after the treatment, respectively, but the pain became very slight only for a short period.

The clinical outcomes of 23 cases diagnosed as pulpitis with pulp exposure were also good for 7 days to 19 months after the treatment, except for 3 cases in which pain on cold water remained 2 weeks, 5 weeks and 5 months after the treatment, respectively. This cold-water sensation might be ascribed by the wide pulp exposure in these cases. However, the evoked sensation became slighter and shorter to a few seconds after the treatment, suggesting the clinical sign was reducing to cease, probable because the exposed holes were narrowing by the formation of calcified materials and re-calcification of soft dentin (8). Pulpal responsiveness to cold was retained after the LSTR 3Mix-MP treatment in all of 38 pulpitis cases.

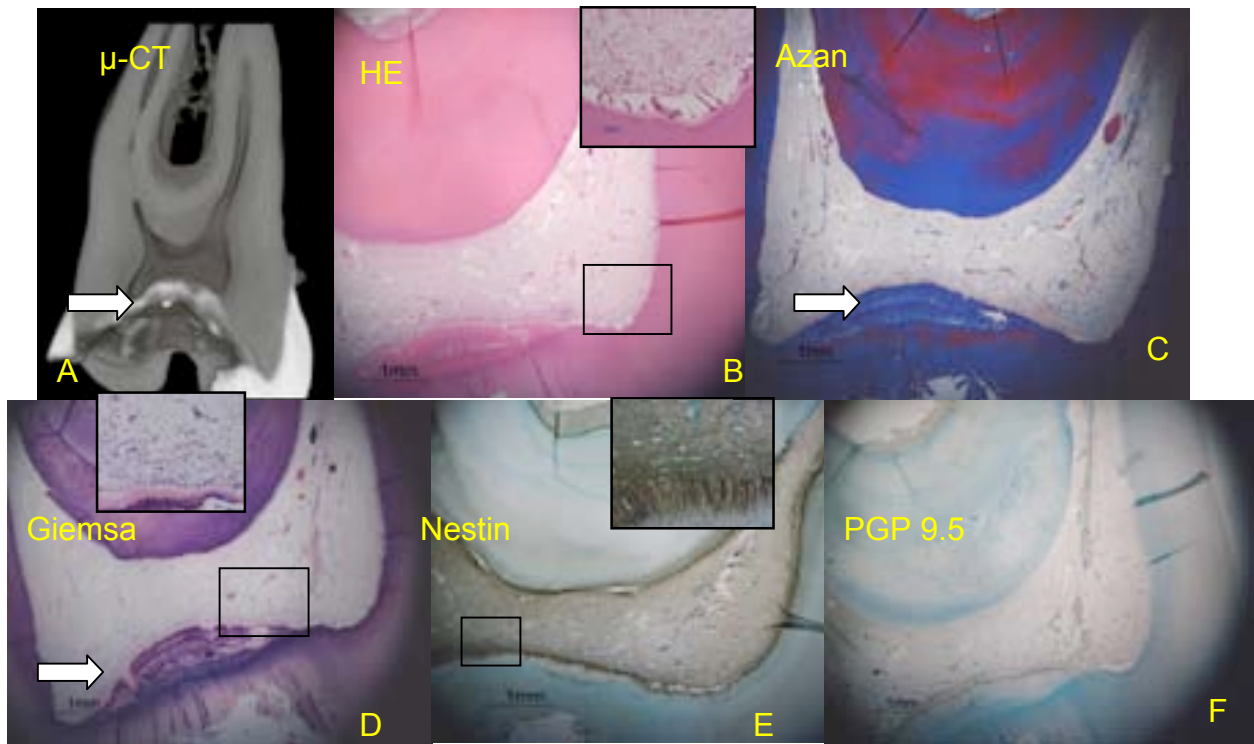
Among 9 cases, diagnosed as necrotic pulp and treated only with the medication of 3Mix-MP without conventional root canal treatment, resulted in good outcomes without any clinical disorders 7days to 18 months after the treatment. As shown in Table 2, pain on bite was not observed any more in all cases. It was striking that, in 5 cases, pulp response was restored against the ethyl chloride coolant at the time of extraction. Remaining 4 cases of necrotic pulp did not feel sensation against the coolants as same as before the treatment.

### **Histopathological observation**

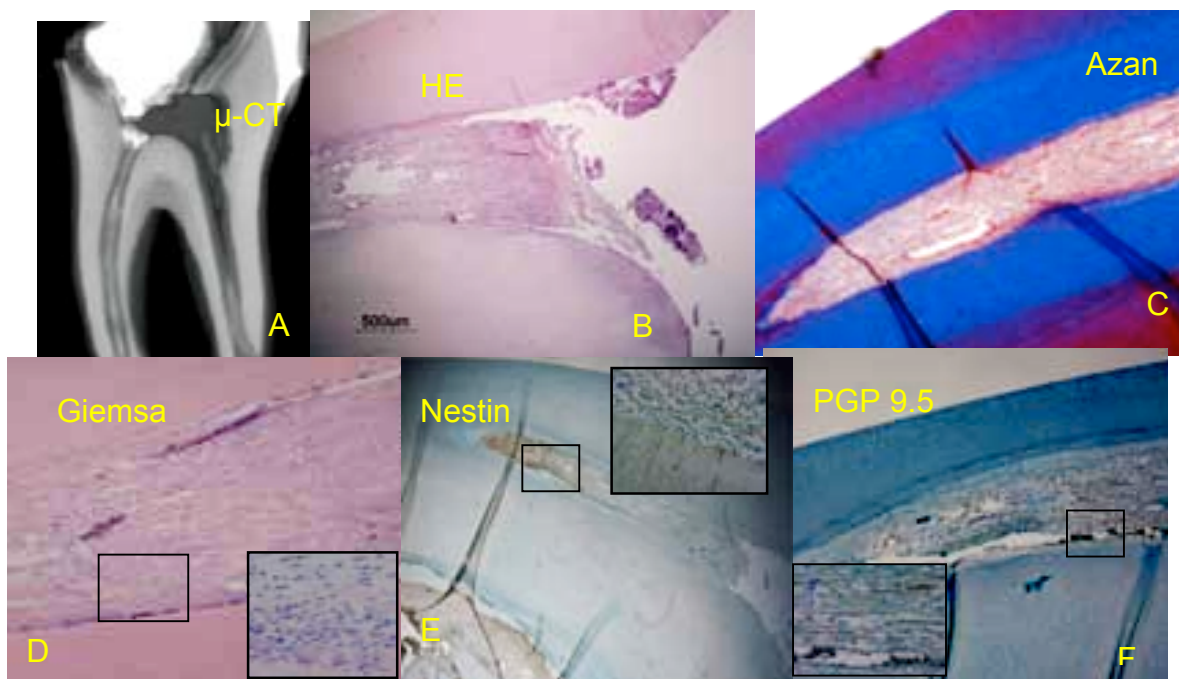
As the consequence of pulpitis and LSTR 3Mix-MP treatment

in 15 cases with spontaneous pain without pulp exposure, it was observed at the time of extraction of the teeth after a certain period (7 days to 19 months) of LSTR 3Mix-MP treatment, lack of odontoblast layers and infiltration of inflammatory cells just beneath the dentin floor of caries cavity were observed in all cases, although such a defect and histopathological changes were rather slight (Fig. 1) even though all the pulps had once infected and inflamed with spontaneous pain. Except for these slight damages, almost all pulp tissue survived and restored pulpal functions demonstrated as the positive Nestin and PGP 9.5 immuno-reactions in all cases. Giemsa staining revealed that the matrix structure of pulp tissue in these cases retained. It was not sure how the pulp tissue had been damaged by the pulpitis and how LSTR 3Mix-MP treatment resulted in the repair of pulp tissue from infective inflammation, but it was quite obvious that, at the time of extraction, pulps were almost entirely surviving 7 days to 10 months after LSTR 3Mix-MP treatment.

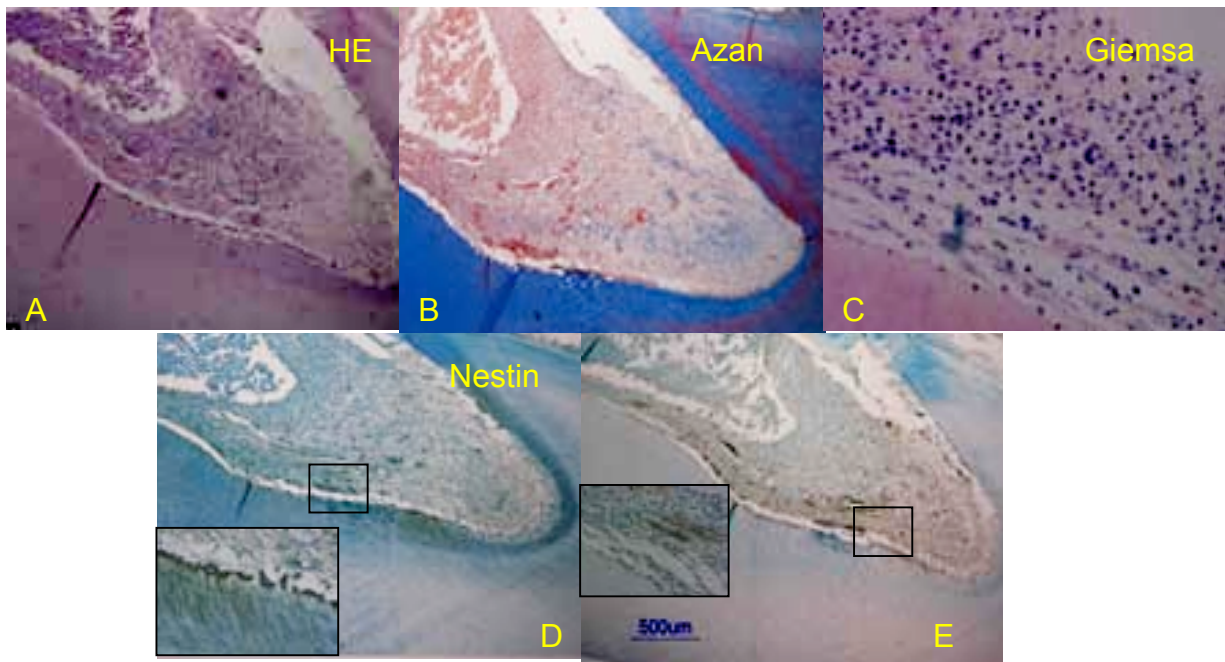
As the consequence of pulpitis with visible pulp exposure in 23 cases, pulp tissue was partly destroyed at limited areas just around the perforation holes at the time of extraction 7days to 19 months after LSTR 3Mix-MP treatment. In the pulp tissue, inflammatory cells were still remained in all cases, and in 17 cases inflammation was rather slight together with positive Nestin and PGP 9.5 immuno-reactions, while in remaining 6 cases inflammatory cells had infiltrated into root canal areas but Nestin and PGP 9.5 immuno-reactions were also positive in these radicular pulps. The Giemsa staining revealed that the matrix structure of pulp tissue in these cases retained. Thus, the pulp damages were considerably slight in these 23 cases (Fig. 2). Additional one case of pulpitis with pulp exposure was not treated for a control, and inflammatory cells had infiltrated into radicular pulp and reached to the apex areas. Despite of this severe inflammation, the pulp tissue was not necrotic, but Nestin and PGP 9.5 immuno-reactions were negative.



**Figure 1.** A pulpitis case without pulp exposure after 10 months treated 3Mix-MP. Calcified tissue lining beneath the cavity floor was observed (arrow). Odontoblasts (B), fibroblasts, collagen fibers, and matrix structure (C) were not damaged in coronal pulp tissue. Nestin positive odontoblasts (E) and PGP 9.5 positive nerve innervation (F) were also observed.



**Figure 2.** A case of pulpitis with exposed pulp. Odontoblasts were disarranged in radicular pulp (B). Calcification was observed in the apical portion 19 months after treatment 3Mix-MP. Damages of fibroblast, collagen fibers and matrix structure were slight (C). Inflammatory cells were partially remained (D), and Nestin positive odontoblasts and PGP 9.5 positive nerve innervation were retained (E, F).



**Figure 3.** A case of radicular pulp after 14 months treated LSTR 3Mix-MP. Inflammatory cells remained (C). However, fibroblast and collagen fibers were reserved (B). Nestin positive odontoblast and PGP 9.5 positive nerve innervation were retained (D, E).

Among 9 cases, diagnosed as necrotic pulps with vacant coronal pulp chambers, 4 cases revealed that entire pulp chamber was empty, although radicular pulps had not been explored to avoid mechanical damages at the time of diagnosis. It was probable that the pulp tissue had been entirely necrotic already at the time of treatment. However, no clinical symptoms claimed after the LSTR 3Mix-MP treatment. Thus, the clinical outcomes of those 4 cases as the dental treatment were evaluated as good. In the remaining 5 cases, root canal pulps remained at the apical one-third, with few inflammatory cells. They were not necrotic, and positive reactions in Nestin and PGP 9.5 immuno-reactions were demonstrated, suggesting they retained/restored pulpal functions.

It was not easy to demonstrate the tissue repair such as dentin bridge formation by the micro CT images, but as shown in Fig 1, calcified layers were observed over the remaining pulp.

## Discussion

In the present study, we aimed to evaluate histopathological changes of pulp tissue, which had once infected and inflamed as pulpitis, after the treatment using LSTR 3Mix-MP treatment. However, histopathological observation needs to extract teeth, and it is ethically impossible to extract functioning teeth after the successful treatment. So, possible rare targets are 3rd molars with pulpitis if the antagonistic teeth are lacking. It is also impossible to compare the histopathological differences on the same teeth before and after the treatment. It is also quite difficult to get the agreement to extract teeth that have been treated successfully and have not caused any clinical disorders for a long time after the treatment, even if the patients once provided informed consents. With these limitations, 48 cases were possible to include in the present study, although the severity of infective inflammation might be different in each case, and different duration from treatment to extraction might affect histopathological images. Pulpal damages, caused by

pulpitis, would be modified by pulpal repairs as the results of disinfection using 3Mix-MP.

With these limitations in mind, in the present study, we evaluated only whether pulpal tissue could survive and whether pulp retained its functions, using Nestin and PGP 9.5 immunochemistry, at the time of extraction regardless the period after the treatment.

So-called irreversible pulpitis is the pulpal conditions under which inflamed pulp tissue had fallen into necrosis, could not survive and would never recovered. Even teeth with reversible pulpitis may be going to fall into irreversible pulpitis unless causative bacteria of infective pulpitis are eliminated to stop and inflammatory tissue destruction. It has been reported that the combination of 3 antibacterial drugs (3Mix) has been proved to kill all the types of oral bacteria (2-5, 12), including those isolated from dental caries, infected pulp lesions and periapical lesions (1, 7). Actually excellent clinical outcomes were obtained in pulpitis treatment using 3Mix-MP without pulpectomy or pulpotomy for the cases with spontaneous pain, with caries lesions extending to pulp chambers on X-ray photos and/or with pulp exposure (8), which had been conventionally considered the cases that needed pulpectomy or pulpotomy. The excellent outcomes of above clinical treatment has confirmed by following up to 2065 days after the treatment, after much longer period than in the present study. Thus, now, it has started to consider to save pulp tissue that had once infected and inflamed, without removal of pulp tissue and to retain the pulp functions. The treatment is called as LSTR 3Mix-MP SavePulp (8).

It was clearly demonstrated histopathologically in the present study, that, after LSTR 3Mix-MP treatment, infected and inflamed pulp tissue survived entirely or in part and pulp functions retained/restored shown as positive immunochemical reaction of Nestin (13) and PGP 9.5 (14). Since the clinical outcomes at the time of extraction in this study were all good and the pulp sensitivity was restored, suggesting that inflamed pulp tissue could be disinfected and sedated by 3Mix-MP. In



general, infective inflammation ceases after elimination of causative bacteria, and the infiltrated inflammatory cells disappear with time. Inflamed pulp tissue may behave the same.

The histopathological results in the present study supported strongly the excellent clinical results of LSTR 3Mix-MP SavePulp therapy done by Takushige et al (8), in which the presence of pulpal responsiveness to cold or electrical stimuli was the only proof of survived pulp tissue without histopathological evaluation. This clinical study together with the results of the present study, it is strongly suggested that it is worth to save pulps without pulpectomy even the cases of pulpitis. However, the clinical study done by Takushige et al. (8) has not included the cases of necrotic pulp. In general, when coronal pulp is fully damaged, there has been no consideration to save remaining root canal pulp, if any. As demonstrated in the present study, root canal pulps may possibly remain, and survive after disinfected and retain/restore pulpal functions. It has been demonstrated that survived pulp tissue after induced pulpitis grow up to the vacant areas of pulp chambers in rat (15) or monkey (16). It is worth to save radicular pulp tissue.

In addition, in the present study, cases of pulpitis and necrotic pulp resulted in good outcomes, including the cases with fully necrotic pulp, after LSTR 3Mix-MP treatment. Conventionally, cases with fully necrotic pulp need root canal treatment using root canal instrumentation and tight root canal obturation. The present study together with other clinical studies (10-11) indicated that, using only medication without conventional procedures for root canal treatment, excellent clinical outcomes have been obtained. Thus, it was strongly suggested that cases of pulpitis, regardless of absence or presence of pulp exposure and remaining pulp tissue, were worth to be treated first aiming to save any parts of pulp tissue, since the present study indicated that LSTR 3Mix-MP treatment could be applicable for the cases not only for pulpitis treatment but also root canal treatment as reported previously (10-11).

It was clearly demonstrated in the present study that the surviving pulp tissue revealed the pulp function, showed by immunochemical positive reactions to Nestin and PGP 9.5. Thus, functioning odontoblasts (13), and nerve innervations (14) were retained/restored in coronal and radicular pulps a certain period after LSTR 3Mix-MP treatment. In recent endodontic study, Banchs and Trope (17) have indicated, when the root canal is disinfected using 3Mix and the inflammatory conditions reversed, the pulp tissue can regenerate as the result of revascularization. In another study conducted by Reni and Hoshino (18), new soft tissue seems to be induced in the sterilized pulp chamber using 3Mix-MP only without revascularization. This study also indicated that it would be necessary to keep pulp chamber sterilized to induce new pulp tissue, and the use of 3Mix-MP is the applicable for this aim, too.

#### Acknowledgment

This work was supported by a grant from Japan Society for the Promotion of Science (JSPS) for the RONPAKU (Dissertation PhD) program Japan.

Supported by the Grants-in-aid for Scientific Research (14406028, and 17390500) from the Ministry of Education, Culture, Sports, Science and Technology, and by the grants for the Joint Research Program from the Japan Society for the Promotion of Science.

#### References

1. Kiryu T, Hoshino E, Iwaku M: Bacteria invading periapical cementum. *J Endod* 1994; 20: 169-72.
2. Hoshino E, Kota K, Sato Mi, Iwaku M: Bactericidal efficacy of metronidazole against bacteria of human carious dentin *in vitro*. *Caries Res* 1988; 22: 280-2.
3. Hoshino E, Kurihara-Ando N, Sato I, Uematsu H, Sato. Mi, Kota K, Iwaku M: *In-vitro* antimicrobial susceptibility of bacteria taken from infected root dentine to a mixture of ciprofloxacin, metronidazole and minocycline. *Int Endod J* 1988; 29: 125-30.
4. Sato T, Hoshino E, Uematsu H, Noda T: In vitro antimicrobial susceptibility to combinations lesions of human deciduous teeth. *Oral Microbiol Immunol* 1993; 8: 172-6.
5. Sato T, Hoshino E, Uematsu H, Kota K, Iwaku M, Noda T: Bactericidal efficacy of a mixture of ciprofloxacin, metronidazole, minocycline and rifampicin against bacteria of carious and endodontic lesions of human deciduous teeth *in vitro*. *Microbial Ecol in Health and Dis* 1992.; 5: 171-7.
6. Cruz EV, Kota K, Huque J, Iwaku M, Hoshino E: Penetration of propylene glycol through dentine. *Int Endod J* 2002; 35: 330-6.
7. Sato I, Ando-Kurihara N, Kota K, Iwaku M, Hoshino E: Sterilization of infected root-canal dentine by topical application of a mixture of ciprofloxacin, metronidazole and minocycline *in situ*. *Int Endod J* 1996; 29: 118-24.
8. Takushige T, Cruz EV, MD. A. Asgor Moral, Hoshino E: Non-surgical treatment of pulpitis, including those with history of spontaneous pain, using a combination of antibacterial drug. *J LSTR Ther* 2008 (International WEB version); 7: 1-5.
9. Tetiana *et al.* (Unpublished data)
10. Takushige T, Cruz EV, MD. A. Asgor Moral, Hoshino E: Endodontic treatment of primary teeth using a combination of antibacterial drugs. *Int Endod J* 2004; 37: 132-8.
11. Takushige T, Hoshino E: Clinical evaluation of 3Mix-MP Method in endodontic treatment. *Jap J Conserv Dent* 1998; 41: 970-4.
12. Hoshino E: Bacteriological aspects of pulpitis. *J Jap Assoc Dent Science* 1992; 11: 119-22 (in Japanese).
13. About I, Laurent-Maquin D, Lendahl U, Mitsiadis TA: Nestin expression in embryonic and adult human teeth under normal and pathological conditions. *Am J Pathol* 2000; 157:287-95.
14. Ramieri G, Anselmetti GC, Baracchi F, Panzic, GC, Viglietti-Panzica C, Modica R, Plak JM: The innervation of human teeth and gingival epithelium as revealed by means of an antiserum for protein gene product (PGP 9.5). *Am J Anat* 1990; 189:146-54.
15. Komoriya T, Arai H, Kota K, Iwaku M: Study on  $\alpha$ TCP for direct pulp capping. *Jap J Conserv Dent* 1986; 29:774-80.
16. Yoshiba K, Yoshiba N, Iwaku M: Effects of antibacterial capping agents on dental pulps of monkeys mechanically exposed to oral microflora. *J Endod* 1995; 21:16-20.
17. Banchs F, Trope M: Revascularization of immature permanent teeth with apical periodontitis: new treatment protocol. *J Endod* 2004; 30(4): 196-200.
18. Reni A, Hoshino E. (unpublished data).

Correspondent Author:

Professor HOSHINO Etsuro

Oral Ecology in Health and Infection,

Niigata University Graduate School of Medical and Dental Sciences

Gakkocho-dori 2, Chu-oh-Ku, Niigata 951-8514 Japan

Fax: +81 (0)25-227-0806; Tel: +81 (0)25-227-2838; e-mail: hoshino@dent.niigata-u.ac.jp